

Blunt aortic injuries caused by high velocity traffic accidents –Open repair vs. TEVAR in multiple injured patients -Observations from a Level-1 trauma centre –

Stephan Brand¹, MD, Ingo Breitenbach², MD, Philipp Bolzen³, MD, Maximilian Petri¹, Max Ettinger⁵, Carl Haasper¹, MD, PhD, Christian Müller¹, MD, Christian Krettek¹, MD, PhD, FRACS, Omke Teebken⁴, MD, PhD, FEBVS

¹Trauma Department Hannover Medical School (MHH), Germany

²Department of Cardiothoracic and Vascular Surgery, Public Hospital Braunschweig, Germany

³Department of Diagnostic Radiology, Hannover Medical School

⁴Department of Cardiothoracic, Transplantation and Vascular Surgery, Hannover Medical School

⁵Department of Orthopedic Surgery, Hannover Medical School

Introduction

Ruptures and dissections of the thoracic and abdominal aortic vessel caused by traffic accidents are rare but potentially life-threatening injuries (1-3). Injuries can occur by blunt trauma via seat belt or dashboard injury, penetrating injuries are more often associated with gunshot or stepping wounds (4-6).

Over the years the treatment algorithm regarding traumatic aortic injuries has changed:

Therapy of blunt traumatic aortic injury mainly depends on the severity of the injury and the anatomical position (7-9).

Only intimal tear injuries are a domain of non-operative treatment, all other types of lesions should be repaired urgently. With the improvements in techniques and diagnostics the treatment algorithm has changed to the frequent use of minimally invasive stents rather than open repair where applicable. The goal of our study was to evaluate the overall mortality, morbidity, neurological disorders, and differences in operative procedures of open repair and stenting.

Material and Methods

From 1977 to 2012 all severely injured patients transferred to our level-1 trauma centre with air rescue unit were screened for blunt traumatic aortic injuries. Severely injured was determined with an ISS of 16 or higher (10). Two groups were formed depending on performed treatment of traumatic aortic injury. Group one was treated with open repair; group two was treated with stentgrafts. Overall-mortality, 30-day mortality, ISS scores and demographic data of both groups were compared.

All patients were seen immediately by trauma surgeons in the emergency unit and treatment algorithm was depending on overall medical situation of the patient and extends of accessory injuries (11).

Ultrasound of the abdominal cavity as well as of the pericardium was performed within minutes after arrival at the hospital. X-rays were taken from chest, pelvic ring and cervical spine as part of the ATLS®-based trauma algorithm (12)(ATLS: Advanced Trauma Life Support). Blood samples were taken and the patient was stabilized with arterial and venous catheters where possible.

Patients were then transferred to the CT-scan for whole body trauma scan, patients before 1987 were diagnosed using digital subtraction angiography (DSA).

Diagnosis of blunt aortic injury was done via multiple-slice CT scan (since 2005 64 slices CT, Image 1).

Besides this, the patient monitoring includes demographic data, collision circumstances, injury pattern, Abbreviated Injury Scale (AIS), Maximum AIS, Injury Severity Score (ISS), incidence of serious or severe multiple injuries.

Decreases in 30-day mortality, in postoperative ICU stay and in transfusion of packed red cell units were expected.

Results

From 1977 to 2012 a total of 45 blunt aortic injuries caused by high velocity traffic accidents transferred to our hospital were observed. All patients suffered blunt trauma to chest and abdominal wall, and all were involved in high-energy traffic accidents.

Those who survived the immediate impact and resuscitation sustained multiple injuries with an average ISS of 41.8 (range 29-68). Some 25 Patients underwent open repair of thoracic aortic injuries between 1977 and 2005 (3 women; 22 men; mean age 27, range 18-69).

These patients were involved in traffic accidents as car driver and motorcycle drivers. The mean ISS in this group was 41.25 (range 29-68).

The second group consisted of 20 patients undergoing emergency stenting of intrathoracic aortic injuries between 2005 and 2012 (18 men; 2 woman; mean age 41.3, range 17-78); the mean ISS was 42.5 (range 29-48). Patients were involved in traffic accidents as car drivers, motorcycle riders and pedestrians.

Surgery was performed on the admission day in both groups and all cases (Image 1).

All patients were transferred to aortic repair within hours after hospital transfer.

In group one open repair via left lateral thoracotomy was performed using gelatin coated woven Dacron tube grafts. For TEVAR thoracic stentgrafts were used and implanted via femoral artery (Medtronic Vascular, Santa Rosa, CA, USA; W.L. Gore & Associates, Flagstaff, AZ, USA, Image 2).

Overall-mortality in both groups was 8/45 (%) and 30-day mortality was 7/45 (%).

Mortality of those undergoing open repair of aortic injury was 6/25 (24%), 30-day mortality 20% (5/25). The average time for open surgery was 151 min; the mean time for stenting was 67 min ($p=0.001$). Postoperative stay on the intensive care unit was between one and 59 days (mean 17) in group one and between four and 50 days in group two (mean 29)($p=0.03$). Patients undergoing open repair required transfusion of 6.0 units of packed red cells in median; patients undergoing stenting required a median of 2.0 units of packed red cells ($p<0.001$).

With those undergoing immediate minimal invasive stenting 30-day mortality was 10% (2/20). The 30-day mortality decreased significantly ($p=0.013$, Mann-Whitney-test).

Neurological deficits were observed with three patients in the open repair group with persistent paraplegia and unilateral vocal cord paralysis in two cases. In the stent group one persistent paraplegia was observed. All but one stent were implanted via femoral artery, in one case a retrograde stenting of the thoracic aorta was performed with open heart massage. This patient died at day six due to multi-organ failure. The left subclavian artery was cross-stent in eight patients, none of these presented with additional neurological deficits.

In the open repair group 22 patients were treated emergently within six hours of hospital admission (88%); in the stent group 18 patients were treated within six hours of admission (90%).

The ISS scores were not significantly higher in the stent group compared to the open repair group (ISS stent 42.5 vs. ISS open repair 41.25; $p= n.s.$).

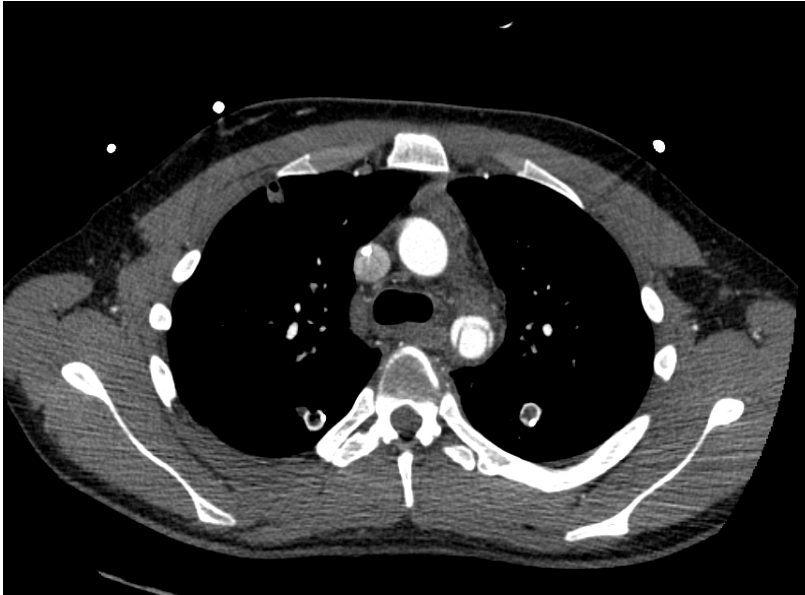


Image 1: Traumatic dissection of the thoracic aorta distally to the left subclavian artery

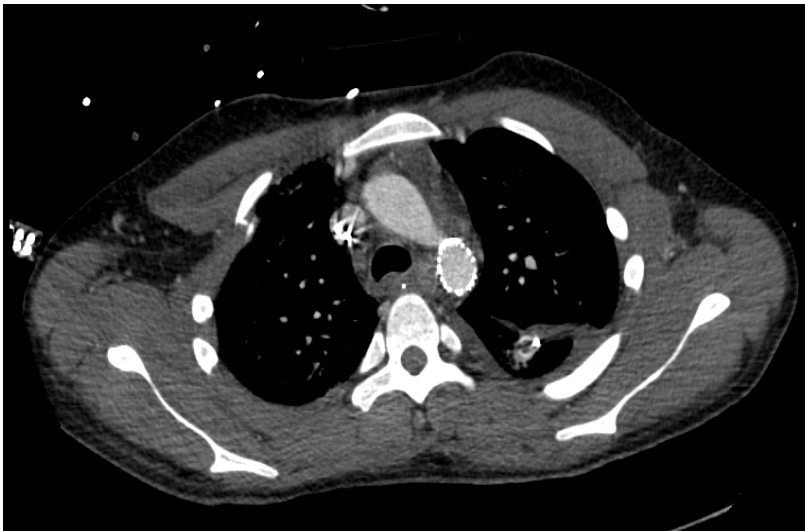

Image 2: Successfully performed minimally invasive stenting of the lesion above

Discussion

There was an increase in patients diagnosed with traumatic aortic injury per year observed since 1995. This could be due to an increase in the quality of prehospital trauma care as well as improvements in diagnostic tools.

The most important finding of our study was a decrease of in-hospital mortality since changes in surgical treatment. From 1977 to 2004 the treatment algorithm consisted of open repair when a traumatic thoracic aortic injury was diagnosed. With the improvement of diagnostic tools (since 2005 64 slices ct scan) and improvements with the use of minimally invasive stentgrafts the in-hospital mortality decreased significantly ($p=0.013$ Mann-Whitney-test).

Furthermore, decrease in transfusion of packed red cell units was significant and time required for surgery was significantly shorter with stenting.

Surprisingly, in contrast to our expectations a significant increase in postoperative ICU stay in the stent group was observed. This could be due to changes in treatment algorithms from early total care orthopedics to damage control surgery (11, 13-15) as well as changes in treatment algorithms of severely injured patients, e.g. continuous lateral rotational kinetic therapy in patients with major thoracic trauma and lung contusion.

Previous investigations showed similar results with a significant lower mortality rate with patients undergoing endovascular repair (6, 16-19). Complications described were type-I endoleaks (17) and partially recovered paraplegia (6).

Conclusion

With the change and improve in diagnostic tools and surgical approach mortality and morbidity of blunt aortic injuries were significantly reduced. Still an immediate life-threatening injury early diagnosis via multiple-slice ct scans and surgical repair with minimally invasive stents showed excellent short-time results for selected patients.

1. P. Goverde *et al.*, Traumatic type B aortic dissection. *Acta Chir Belg* **96**, 233 (Sep-Oct, 1996).
2. C. H. Marty-Ane *et al.*, Intravascular stenting of traumatic abdominal aortic dissection. *J Vasc Surg* **23**, 156 (Jan, 1996).
3. S. A. Stamenkovic, P. R. Taylor, J. Reidy, J. C. Roxburgh, Emergency endovascular stent grafting of a traumatic thoracic aortic dissection. *Int J Clin Pract* **58**, 1165 (Dec, 2004).
4. H. Turhan, S. Topaloglu, K. Cagli, H. Sasmaz, E. Kutuk, Traumatic type B aortic dissection causing near total occlusion of aortic lumen and diagnosed by transthoracic echocardiography: A case report. *J Am Soc Echocardiogr* **17**, 80 (Jan, 2004).
5. G. Zoffoli, S. Saccani, P. Larini, A. Colli, T. Gherli, Endovascular treatment of traumatic aortic dissection and innominate artery pseudoaneurysm. *The Journal of trauma* **61**, 447 (Aug, 2006).
6. X. Y. Zhang, D. M. Di, N. Q. Jiang, Y. X. Qian, X. H. Zhan, Emergent treatment of patients with traumatic aorta ruptures. *Chin J Traumatol* **10**, 163 (Jun, 2007).
7. M. E. DeBakey *et al.*, Surgical Management of Dissecting Aneurysms of the Aorta. *J Thorac Cardiovasc Surg* **49**, 130 (Jan, 1965).

8. M. E. DeBakey, E. S. Crawford, H. E. Garrett, A. C. Beall, Jr., J. F. Howell, Surgical considerations in the treatment of aneurysms of the thoraco-abdominal aorta. *Ann Surg* **162**, 650 (Oct, 1965).
9. P. O. Daily, H. W. Trueblood, E. B. Stinson, R. D. Wuerflein, N. E. Shumway, Management of acute aortic dissections. *Ann Thorac Surg* **10**, 237 (Sep, 1970).
10. C. Haasper *et al.*, [The Abbreviated Injury Scale (AIS). Options and problems in application]. *Der Unfallchirurg* **113**, 366 (May, 2010).
11. H. C. Pape *et al.*, Timing of fracture fixation in multitrauma patients: the role of early total care and damage control surgery. *J Am Acad Orthop Surg* **17**, 541 (Sep, 2009).
12. J. K. Styner, The birth of Advanced Trauma Life Support (ATLS). *Surgeon* **4**, 163 (Jun, 2006).
13. C. Krettek, R. G. Simon, H. Tscherne, Management priorities in patients with polytrauma. *Langenbecks Arch Surg* **383**, 220 (Aug, 1998).
14. H. C. Pape, Effects of changing strategies of fracture fixation on immunologic changes and systemic complications after multiple trauma: damage control orthopedic surgery. *J Orthop Res* **26**, 1478 (Nov, 2008).
15. H. C. Pape *et al.*, Changes in the management of femoral shaft fractures in polytrauma patients: from early total care to damage control orthopedic surgery. *The Journal of trauma* **53**, 452 (Sep, 2002).
16. W. A. Lee *et al.*, Endovascular repair of traumatic thoracic aortic injury: clinical practice guidelines of the Society for Vascular Surgery. *J Vasc Surg* **53**, 187 (Jan, 2011).
17. I. E. Steingruber *et al.*, Placement of endovascular stent-grafts for emergency repair of acute traumatic aortic rupture: a single-centre experience. *Eur Radiol* **17**, 1727 (Jul, 2007).
18. H. Rousseau *et al.*, Acute traumatic aortic rupture: a comparison of surgical and stent-graft repair. *J Thorac Cardiovasc Surg* **129**, 1050 (May, 2005).
19. D. K. Lawlor *et al.*, Endovascular management of traumatic thoracic aortic injuries. *Can J Surg* **48**, 293 (Aug, 2005).